

ISSN: 3032-1085



UDC: 616.21: 616-092: 612. 017.1.064-053.2: 615.37

CLINICAL FEATURES OF OTITIS MEDIA IN PATIENTS WITH HIV INFECTION

Alimova Sh.A.

Bukhara State Medical Institute

Received: Des 11, 2023; Accepted: Jan 11, 2023; Published: Feb 11, 2024;

Annotation. The work was carried out at the clinical base of the Bukhara State Medical Institute - and at the regional multidisciplinary clinical hospital. Analyzed data of examination and treatment of 75 patients from 18 to 60 years old, with ENT pathology against the background of HIV infection for the period from 2020-2021. Also examined were 30 non-HIV-infected patients of the same age and sex. All patients underwent a comprehensive examination, including otorhinolaryngological, clinical laboratory, bacteriological, and immunological studies.

HIV-infected patients are characterized by frequent exacerbations of ENT diseases, in which 78.8% of patients were hospitalized due to the severity of the disease, and 21.2% of patients were treated in an outpatient setting. Severe and complicated forms of ENT disease occurred at a high frequency against the background of HIV infection, accounting for 23%. Of the complications that developed against the background of HIV infection, 13.4% were meningitis, 7.7% were brain abscesses, 1.9% were severe sepsis, and 9.6% were fatal.

Key words: HIV-infected patients, non-HIV-infected patients, acute otitis media, chronic otitis media.

Relevance. The problem of diagnosis and treatment of acute and chronic forms of pathologies of ENT organs is confirmed by the fact of a high degree of morbidity and treatment of patients to GPS and ENT doctors. The prolonged, chronic course of the disease, cases of systemic inflammation syndrome (SIRS – systemic inflammatory response syndrome), the development of severe, life-threatening complications remain unsolved to date [1;6;10;15]. This problem acquires its vital relevance not only for otorhinolaryngologists, but for the entire practical medicine as a whole. A very extensive group of inflammatory diseases are infectious pathologies of the ENT organs, each of which a person is "able" to tolerate several times in his life [21;22].

Acute otitis media – (AOM) is the most common pathology in young children. If during the first 7 years of life, 95% of children have a history of at least one episode of the incidence of AOM, then by the age of 3, this indicator is 71%. According to the HMO (Health Maintenance Organization), a large number of children (48%) have single episodes of acute perforated or non-perforated AOM in the first 6 months of life or more than 2 episodes in 12 months. Life [2;8;9;11]. In the pathogenesis of AOM, the leading place is given to the destruction of the patency of the auditory tube, which leads to the creation of negative pressure in the tympanic cavity and fluid transudation.

Also, today, there is a tendency to increase in the number of patients infected with HIV infection in many countries of the world. Analysis of data from the scientific literature of this direction shows that in the first year of life 14% of children infected with HIV by the perinatal pathway and not treated prophylactically were diagnosed with AIDS, in the following years 11-12% were

diagnosed with AIDS, and in half of children the last stage of AIDS was detected [3;7;12;14]. According to a number of authors, bacterial lesions of the mucous membranes and skin may indicate the first manifestations of immunodeficiency. It is not always possible to see the development of immunodeficiency with a banal infection of the ENT organs. The frequent occurrence of otitis media, sinusitis, frequent angina, being the features of the clinic, should alert the otorhinolaryngologist, as well as the lack of a pronounced effect from the treatment, in the case of chronization and frequent exacerbations. There is an elongated development cycle, boils and carbuncles occur more often, the treatment of which is ineffective [4;5;13;16]. Bacterial infections in HIV-infected individuals are due to the fact that they are in association and thus act in the body. The final effect can be gingivitis in HIV infection, HIV-necrotic lesions of the gums and/or mucous membranes of the cheeks, palate, tonsils, posterior pharyngeal wall, nasal cavity, up to the formation and "formation" of a general perforation of the nasal septum, HIV - chronic periodontitis and stomatitis. Exacerbations of chronic ENT pathologies are a common cause of the development of acute sinusitis, purulent otitis media with complications [3;8;17;19].

The results of three controlled trials on the prevalence of acute otitis media in HIV-infected children have been published. All of them show that the frequency of this disease in HIV- infected children is not increased, but among children with clinical manifestations of HIV infection, relapses of otitis media are much more common [1;4;18;20].

To date, there is insufficient data on the course of bacterial diseases of the ENT organs in HIV- infected children, in particular, on the frequency and nature of the otorhinolaryngological manifestation of HIV infection in children.

Purpose of the study. Conducting a detailed clinical analysis of the structure of patients with acute and chronic diseases of the middle ear and the influence of HIV infection in the dynamics of the development of the pathological process.

Materials and methods. The work was performed at the clinical base of the Bukhara State Medical Institute and the regional multidisciplinary clinical hospital. The data of examination and treatment of 75 patients from 18 to 60 years old with ENT pathology on the background of HIV infection for the period from 2020-2021 were analyzed. 30 non-HIV-infected patients of the same age and gender were also examined. All patients underwent a comprehensive examination, including otorhinolaryngological, clinical and laboratory, bacteriological, and immunological studies.

Results of the study. The patients were divided into groups according to the following indicators: 1. Patients with acute otitis media 25 patients, including HIV-negative 7 patients, HIV-positive -18; 2. Patients with chronic otitis media -50, HIV-negative 16 and HIV-positive 34.

Table 1.1

Distribution of patients with HIV infection, taking into account age and gender

Gender	Age of patients						Total	
	18-25 years		25-39 years		39-60 years			
	Aбс	%	Aбс	%	абс	%	абс	%
Men	7	15,5	17	37,8	11	24,4	45	60
Women	6	20	14	46,7	10	33,3	30	40

It is noteworthy that in all the studied age groups, depending on the sexual characteristic, the lesion of the ENT organs is dominated by the number of men from the total number of patients, mainly at the age of 25-39 years Table 1.1. It is difficult to explain this pattern, apparently, the reason lies in the biological sexual characteristics of the organism that are still unclear to us.

A comparison of the frequency of otitis media in HIV-infected and HIV-uninfected patients is shown in Table 1.2. As can be seen from the table, the most common nosology is chronic purulent mesotimpanitis, which was detected in HIV-infected children (33.8% vs. 56.5% in the control group). There is no significant difference between the groups ($P>0.05$).

Table 1.2

Frequency of occurrence of otitis media in HIV-infected and non - HIV-infected patients

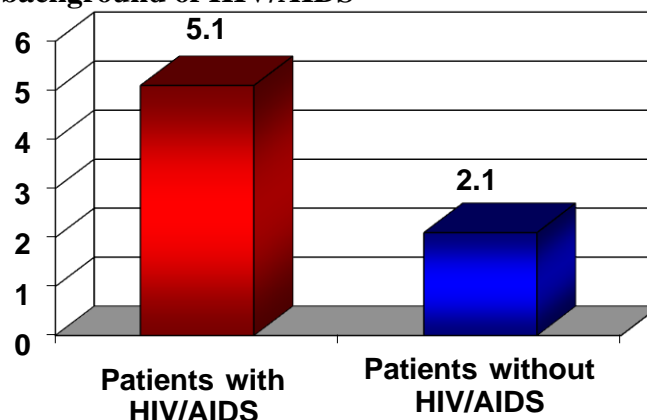
Nosology	People are infected with HIV		People are not infected with HIV		Death indicator			
					Patients with HIV		Patients without HIV	
Acute otitis media (pre-perforative stage)	4	6,2	2	8,7	1	8,3	0	0
Acute otitis media (perforative stage)	14	21,5	5	21,7	0	0	0	0
Chronic purulent mesotimpanitis	22	33,8	13	56,5	0	0	0	0
Chronic purulent epithympanitis	12	18,5	3	13,0	11	91,7	1	8,3
General:	52	69,3	23	30,7	12	23,1	1	1,9

The frequency of acute otitis media of the perforated stage in the control group is more common. It can be seen that otitis prevailed in patients with HIV infection.

The study of anamnestic data showed that the annual recurrence of chronic otitis media in the group with HIV/AIDS reached from 3 to 8 times and averaged 5.1 ± 0.2 times. In the group without HIV infection, this indicator was significantly lower, amounting to 2.1 ± 0.3 times a year ($P<0.001$) (Fig.1.1).

Figure 1.1

Average number of exacerbations of middle ear disease per year in patients without HIV and against the background of HIV/AIDS



Against the background of a greater number of exacerbations of chronic otitis media for patients with HIV/AIDS is also characterized by a higher incidence of severe forms of the disease (Figure

1.2). Thus, out of 52 patients in 12 (23%) cases, the clinical course of middle ear diseases was severe, while in the control this indicator was only 1 (4.3%) patients (according to the criterion $\chi^2=9,365$; $df=1$; $P=0.002$).

Among HIV-infected patients, 12 had hearing disorders: 4 (33.3%) had conductive hearing loss, and 8 (66.7%) had sensorineural hearing loss.

Table 2.15

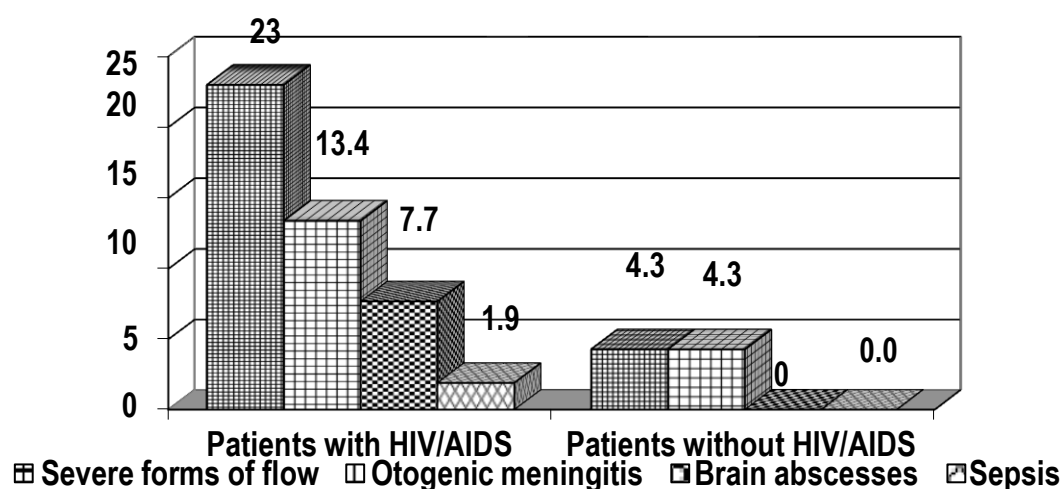
Audiometry of HIV-infected sick children (with ear pathology)

Threshold audiometry	Patients with HIV		Patients without HIV	
Threshold audiometry conductive hearing loss	4	33,3	4	44,4
Threshold audiometry sensorineural hearing loss)	8	66,7	5	55,6
General:	12	57,1	9	42,9

Among the complications, meningitis, sepsis and the development of brain abscesses should be distinguished.

Figure 1.2.

Severe forms of middle ear disease in patients without HIV and on the background of HIV/AIDS.

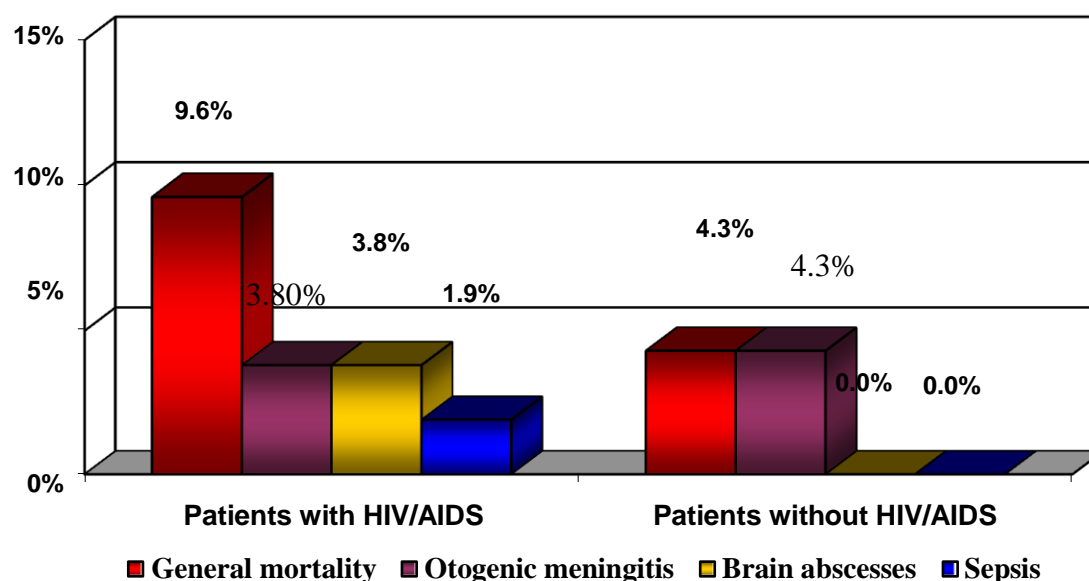


In the group with HIV/The incidence of meningitis was observed in 7 (13.4%) patients, in the control group – in 1 (4.3%) patient; brain abscesses were noted in 4 (7.7%) patients with HIV/AIDS; sepsis developed in 1 (1.9%) (according to the criterion $\chi^2=9.742$; $df=3$; $P=0.027$). It should be noted that in the complication "sepsis" only isolated forms are given, and the true values in the group of children with HIV/AIDS were significantly higher (included in the number of meningitis and abscesses).

In our group of patients, the mortality rate against the background of severe complications of otitis media on the background of HIV or AIDS was (9.6%), while in the control group this indicator was (4.3%) a patient who was admitted with severe otogenic meningitis. The cause of the fetal outcome was meningitis in 2 (3.8%) cases, brain abscesses – in 2 (3.8%) cases and sepsis - in 1 (1.9%) case (Fig. 1.3).

Figure 1.3.

Mortality rate in complications of otitis media in HIV-infected and non-infected patients

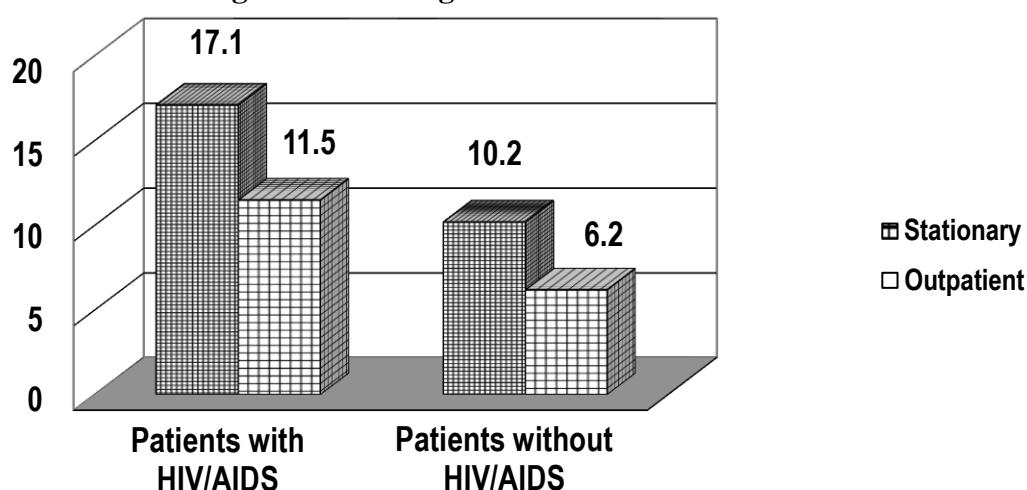


It should be noted that the development of these otogenic complications against the background of acute and chronic diseases in patients with HIV/AIDS can be irreversible in almost a third of cases. Thus, for 7 cases of meningitis, 2 (3.8%) patients died, for 4 cases of brain abscess – 2 (3.8%) and for 1 case of severe sepsis – 1 (1.9%) patient.

The duration of outpatient treatment for acute and chronic diseases of the middle ear on the background of HIV averaged 11.5 ± 0.4 days, while without HIV – 6.2 ± 0.3 days ($P < 0.001$). Duration of treatment in inpatient conditions for acute and chronic diseases of the middle ear on the background of HIV/AIDS reached 17.1 ± 0.6 days versus 10.2 ± 0.4 days in the group of patients without HIV ($P < 0.001$) (Fig. 1.4).

Figure 1. 4.

The average duration of outpatient and inpatient treatment for diseases of the middle ear in patients without HIV and against the background of HIV/AIDS



Conclusion. 1. Frequent exacerbations of ENT-member diseases in patients infected with HIV are characteristic (5.1 ± 0.2 times a year, in patients not infected with HIV 2.1 ± 0.3 times $P < 0.001$), in which 78.8% of patients due to the severity of Avoli were hospitalized (43.5% in patients not infected with HIV, $P < 0.001$), 21.2% of patients treated in outpatient settings (56.5% in patients not you know what?

2. Severe and complication types of ENT-member diseases were found at a high frequency

against the background of HIV infection and accounted for 23% (4.3% in the control group) ($P < 0,002$). 13.4% of the complications developed against the background of HIV infection were meningitis, 7.7% brain abscess, 1.9% ($P < 0,027$) severe sepsis, causing death in 9.6% of cases.

References

1. Nurov U. I., Ikramova F. S. Features Of Non-Specific Protection Factors And Cytokine Status In Inflammatory Diseases Of The Paranasal Sinuses In Twin Children //The american journal of medical sciences and pharmaceutical research. – 2021. – Т. 3. – №. 02. – С. 118-126.
2. Ikramova F.S., & Toyirov M.M. (2022). THE PREVALENCE OF CHRONIC RHINOSINUSITIS AMONG ENT PATHOLOGIES IN PRESCHOOL AND SCHOOL-AGE CHILDREN AT THE HOSPITAL STAGE OF MEDICAL CARE. Conferencea, 463–466.
3. Nurov U. I., Ikramova , F. S., & Alimova , S. A. (2022). Immunological Aspects of Chronic and Recurrent Acute Rhinosinusitis in Children. Central Asian Journal of Medical and Natural Science, 3(3), 31-35.
4. F. S., I., & Sh. A., A. (2023). Clinicofunctional Efficacy of Complex Treatment of Chronic Adenoiditis Using Phototherapy. European Journal of Medical Genetics and Clinical Biology, 1(1), 53–56.
5. F.S., I., & Sh.A., A. (2023). Complex Treatment of Chronic Adenoiditis Using Phototherapy. European Journal of Medical Genetics and Clinical Biology, 1(1), 36–38.
6. F. S., I. (2022). The Significance of Diseases of the Gastrointestinal Tract in the Clinical Course of Allergic Rhinitis. Miasto Przyszłości, 28, 97–98.
7. U. I. Nurov, F. S. Ikramova, Sh. A. Alimova Functional status of immune status in inflammatory diseases of the paranasal sinuses in twin children // Academic research in educational sciences. 2021. №5.
8. F. S. Ikramova, & M. M. Toyirov (2022). THE PREVALENCE OF CHRONIC SINUSITIS IN THE PEDIATRIC POPULATION. Scientific progress, 3 (4), 38-41.
9. Ikramova, F. S. "Barakatov IB Allergicheskiy rinit i funktsionalnoe sostoyanie pecheni." Molodej-prakticheskomu zdravooxraneniyu-2018.-S: 440-441.
10. Shahnoza Azamatovna Alimova The incidence and clinical features of otitis media in patients with hiv infection // Scientific progress. 2021. №5.
11. Ulugbek Nuridinovich Vokhidov, Khusniddin Noriddinovich Nuriddinov Analysis of the frequency of distribution and treatment methods for polypous rhinosinusitis Journal of Biomedicine and Practice Volume 4 Issue 5. 2020
12. АЛИМОВА Шахноза Азаматовна ЭТИОПАТОГЕНЕТИЧЕСКИЕ ОСОБЕННОСТИ СРЕДНЕГО ОТИТА У БОЛЬНЫХ ВИЧ-ИНФЕКЦИЕЙ // Научный прогресс. 2021. №5.
- 13.
14. Nurova, G. U., and U. I. Nurov. "The current state of study of vasomotor rhinitis modern diagnostic and therapeutic methods" American journal of medicine and medical sciences-USA 10.4 (2020).
15. Nurov U. I., Ikramova F. S., Alimova S. A. Immunological Aspects of Chronic and Recurrent Acute Rhinosinusitis in Children //Central Asian Journal of Medical and Natural Science. – 2022. – Т. 3. – №. 3. – С. 31-35.

16. Шахноза Азаматовна Алимова (2021). ЧАСТОТА И КЛИНИЧЕСКИЕ ОСОБЕННОСТИ СРЕДНЕГО ОТИТА У ПАЦИЕНТОВ С ВИЧ-ИНФЕКЦИЕЙ. Научный прогресс, 2 (5), 74-81.
17. Nurov U. I., Nurova G. U., Rashidov D. R. THE INCIDENCE OF RHINOSINUSITIS AMONG ENT DISEASES IN SCHOOL-AGE CHILDREN //Scientific progress. – 2022. – Т. 3. – №. 4. – С. 28-31.
18. Firangiz Suleymanovna Ikramova (2022). IMPORTANCE OF IMMUNOLOGICAL PARAMETERS IN THE CLINICAL COURSE OF PURULENT OTITIS MEDIA. Scientific progress, 3 (1), 151-156.
19. Shaxnoza Azamatovna Alimova (2022). ЭТИОПАТОГЕНЕТИЧЕСКАЯ ХАРАКТЕРИСТИКА СРЕДНЕГО ОТИТА У ВИЧ ИНФИЦИРОВАННЫХ ПАЦИЕНТОВ. Scientific progress, 3 (1), 198-207.
20. Х. Н. Нуриддинов, Ш. А. Алимова (2022). АНАЛИЗ РЕЗУЛЬТАТОВ ЭНДОСКОПИЧЕСКОЙ ДИАГНОСТИКИ И ЛЕЧЕНИЯ ХРОНИЧЕСКОГО ПОЛИПОЗА, РИНОСИНУСИТА. Научный прогресс, 3 (5), 155-161.
21. Ш. А. Алимова (2022). МОРФОМЕТРИЧЕСКИЕ ИЗМЕНЕНИЯ В РАЗВИТИИ МИКРОСОСУДОВ АНАЛЬНОГО КАНАЛА И СПИНКТЕРНОГО АППАРАТА ПРЯМОЙ КИШКИ У КРЫС НА РАЗНЫХ ЭТАПАХ ПОСТНАТАЛЬНОГО ОНТЕНОГЕНЕЗА. Scientific progress, 3 (4), 52-56.
22. Нафиса Ботировна Саидмуродова, Шахноза Азамат Қизи Алимова, & Фирангиз Сулеймановна Икрамова (2021). ТУҒМА ТАНГЛАЙ КЕМТИКЛИГИ БЎЛГАН БОЛАЛАРДА ПАРАНАЗАЛ СИНУСЛАРНИНГ ФУНКЦИОНАЛ ҲОЛАТИ. Scientific progress, 2 (4), 404-411.