

EVALUATE THE EFFECT OF ORLISTAT, LIRAGLUTIDE, AND THE HERBAL SUPPLEMENT ON THE MOTHERS OF EXPERIMENTALLY FATTENED WHITE RATS

Zainab Hasan Majeed

Biology Dept., College of Education for Women, Tikrit
University, Iraq

Zaiynab.hassan@uokirkuk.edu.iq

Ektifa Abdul Hamid Muhammad

Biology Dept., College of Education for Women, Tikrit
University, Iraq

Muna Salah Rasheed

Biology Dept., College of Sciences, Tikrit University, Iraq

Received: Feb 22, 2024; Accepted: March 29, 2024; Published: Apr 18, 2024;

Abstract: The current study aimed to evaluate the effect of orlistat, liraglutide, and the herbal supplement on the mothers of experimentally fattened white rats. The female rats were divided into two main groups, the first fed a standard ration, in which two groups were the first pregnant and the second non-pregnant, while the second main group was fed a special diet containing 35% fat for the purpose of fattening as a first stage and for a period of 6 weeks, then the second stage began, which is the pregnancy and treatment stage and included eight secondary groups. The first group was not treated with any drug, the second group was orlistat at a therapeutic dose, the third group was liraglutide at a therapeutic dose, the fourth group was an herbal supplement, and the fifth group was a supplement with a therapeutic dose. Of Orlistat, the sixth group is supplemented with a therapeutic dose of liraglutide, the seventh group is a high dose of orlistat, and the eighth group is a high dose of liraglutide. The current study showed that the obesity leads to changes in lipid profiles compared to control groups, as the effect of fattening is represented by an increase in the concentration of total cholesterol, triglycerides, low-density lipoproteins, very low-density lipoproteins, and a decrease in high-density lipoproteins, histological examinations. Pathological changes appeared in each of the liver tissues, represented by a large proliferation of fat droplets, steatosis, Müller bodies, collapse of the central vein wall, and lymphocytic infiltration. The two best groups were when the herbal supplement was used with both drugs, and the herbal supplement had a synergistic role. With the two drugs, it reduces the accumulation of fat in the cells.

Keywords: Orlistat; liraglutide; Obesity; Total cholesterol; HDL.



This is an open-access article under the [CC-BY 4.0](https://creativecommons.org/licenses/by/4.0/) license

Introduction

Obesity is defined as a multifactorial disease, derived from the Latin word *obesus*, which means pumping fat into the body. Obesity occurs due to an imbalance between calories taken in and energy expended. Obesity is considered a global health problem because it is linked to serious diseases such as heart disease, cancer, and diabetes and is closely linked to increased premature mortality rates [1]. Obesity is characterized by an increase in adipose tissue due to the metabolic state [2]. Studies have indicated that obesity is increasing in Iraq. A survey was conducted in 2006 with the support of the World Health Organization, which revealed that the obesity rate was high, about 66.9%. Al-Tawil et al., [3] showed that (37%) of Baghdad's population suffered from obesity, and (39%) of them were women, while in Basra, the rate of obesity was about 55% [4]. The high cost of surgery, postoperative follow-up, and complications make it unlikely to be a universally accepted treatment for the majority of patients with obesity. Thus, medications that prevent weight regain appear to be essential in the treatment of obesity. In light of this, several anti-obesity drugs have been developed and used, such as sibutramine and rimonabant, but due to their serious side effects, drug safety organizations have considered anti-obesity drugs a controversial issue [5]. Several studies have shown that using orlistat for a year with energy-restricted diets leads to weight loss with exercise, so orlistat has a role in lowering blood pressure and diabetes [6]. On the other hand, FDA approval was obtained in 2014, and in 2019 the organization gave confidence to use liraglutide as a treatment for children aged ten and above who suffer from type 2 diabetes, thus making it the first non-insulin-based drug to treat diabetes [7]. GLP-1R receptors are located on neurons in the hypothalamus, which contains appetite control centers, and thus liraglutide works to reduce weight [8]. At the present time, people prefer to use natural materials found in plants, especially the foods that we eat daily, as it has been discovered that these foods and supplements contain biosynthetic compounds they affect weight loss in several ways, such as reduces inhibition of adipocyte differentiation, interferes with lipid synthesis enzymes [9]. Therefore, The current study aimed to evaluate the effect of orlistat, liraglutide, and the herbal supplement on the mothers of experimentally fattened white rats.

Methods

Experiment animals

100 female albino rats were used in this study. Obtained from the General Company for Pharmaceutical Industry. Female rats were kept in the animal house in wire mesh stainless cages (two animals per one cage). The environment was controlled in the animal cages, where the temperature was maintained at (20-24°C), and the lighting was 12:12 hours light: dark cycle with good ventilation.

Experiment design

Groups were distributed such that each group contained 10 females, and these groups were as follows:

1. Group A: 10 non-pregnant female rats were dissected on day 18 of pregnancy for the other of the groups.
2. Group B: 10 pregnant female rats were dissected on the 18th day of pregnancy.
3. Group C: 10 pregnant and obese female rats were dissected on the 18th day of pregnancy.
4. Group D: 10 pregnant female rats were dosed with orlistat (therapeutic dose) on day 18 of pregnancy.
5. Group E: 10 pregnant female rats were dosed with liraglutide (therapeutic dose) on day 18 of pregnancy.
6. Group F: 10 pregnant female rats were dosed with Slim herb on the 18th day of pregnancy.

7. Group G: 10 pregnant female rats were dosed with the herb and the drug orlistat (a therapeutic dose) on the 18th day of pregnancy.
8. Group H: 10 pregnant female rats were dosed with the herb and liraglutide (a therapeutic dose) on the 18th day of pregnancy.
9. Group J: 10 pregnant female rats were dosed with orlistat (over dose) on day 18 of pregnancy.
10. Group K: 10 pregnant female rats were dosed with liraglutide (over dose) on day 18 of pregnancy.

Measurements of lipid profile by cobas

The enzymatic cholesterol, triglycerides and HDL assay as described by Eggstein and Kreutz still required saponification with potassium hydroxide. Roche/Hitachi cobas systems automatically calculate the analyte concentration of each sample.

Histological study

Fresh hearts from each rat were rapidly dissected, fixed with 10% formalin, and dehydrated with ethanol in escalating concentrations. After tissue samples had been dehydrated, they were cleared in two changes of xylene, impregnated in three exceptions of molten paraffin wax, embedded, and blocked out. Sections with a 5 μ m thickness were stained with haematoxylin-eosin [10].

Statistical analysis

Version 18 of the SPSS application (Statistical Package for Social Science) was used to code and enter the data onto a computer for statistical analysis. Every data point was organized based on frequency, and the Chi-square test was used to examine correlations between variables. A p-value of less than 0.05 was deemed significant.

Results and Discussion

Lipid profile

Table (1) showed that there was a significant ($P < 0.05$) increase in the concentration of total cholesterol, triglycerides, LDL and VLDL in the group treated with a high-fat diet during pregnant women compared to the non-pregnant control group and the group of non-obese pregnant women, while a significant ($P < 0.05$) decrease was recorded in all groups treated with both Orlistat and Liraglutide and the herb compared with the obese group. The results also recorded a significant ($P < 0.05$) decrease in the two groups that were dosed with high doses of both Orlistat and Liraglutide compared to the rest of the groups. On the other hand, there was a significant ($P < 0.05$) decrease in HDL concentration in the group treated with a high-fat diet for pregnant women compared to the non-pregnant control group and the non-obese pregnant group, while a significant ($P < 0.05$) increase was recorded in all groups treated with Orlistat and Liraglutide, and the herb compared with the obese group, as well. The results recorded an improvement and a significant ($P < 0.05$) increase in the two groups that were dosed with high doses of both Orlistat and Liraglutide compared to the rest of the groups.

Table (1): the levels of lipid profile in studied groups

Parameters Groups	Total cholesterol	Triglyceride	HDL	LDL	VLDL
GA	95.4 \pm 9.34 d	75.7 \pm 9.61 e	34.5 \pm 3.21 a	45.4 \pm 9.65 d	15.54 \pm 2.03 c
GB	108.1 \pm 7.05 d	83.1 \pm 7.5 e	30.7 \pm 4.51 a	57.8 \pm 7.04 d	16.62 \pm 3.11 c
GC	167.7 \pm 9.39 a	172.3 \pm 15.01 a	19.7 \pm 3.16 b	114.1 \pm 14.6 a	33.86 \pm 4.17 a
GD	143.9 \pm 7.04 b	143.2 \pm 8.38 b	24.5 \pm 2.42 b	90.76 \pm 9.17 b	28.64 \pm 3.55 a

GE	138.4±9.91 b	129.7±12.5 c	23.9±3.47 b	88.56±8.31 b	25.63±4.73 b
GF	129.3±4.58 bc	123.7±13.5 c	24.3±2.95 b	79.06±6.93 c	24.15±2.52 b
GG	119.5±7.44 c	112.8±6.93 d	28.1±3.61 a	68.44±8.24 c	22.85±3.17 b
GH	121.9±5.5 bc	82.3±14.7 e	29.7±4.21 a	75.94±5.93 c	16.26±2.15 c
GJ	126.5±7.41 bc	73.3±10.4 e	31.8±5.31 a	80.2±11.8 bc	14.46±2.15 c
GK	117.1±6.39 c	80.6±7.41 e	33.6±4.04 a	67.18±6.52 c	16.32± 4.12c

*same letters mean there is non-significant ($P \leq 0.05$) differences, different letters mean there is significant ($P \leq 0.05$) differences.

The increase in levels of lipid profiles in the pregnant group can be explained by increased levels of the hormones estrogen, progesterone, and placental lactogen and as a normal physiological state during pregnancy, as The levels of fatty acids, glucose, amino acids were increase to ensure the preservation of energy sources in the body used as a source of growth and fetal development [11]. The current study agrees with Hussein and Mustafa [12] that a high-fat diet causes an increase in the level of low-density lipoprotein (LDL) and this explains the increase in its level in the current study. The reason for the decrease in high-density lipoprotein (HDL) may be due to an increase in very low-density lipoprotein (VLDL) manufactured in the liver due to the pumping of large amounts of fatty acids into it because they increase in the body due to obesity, thus activating the receptors called cholesterol ester transfer protein (CETP) which plays a role in the HDL metabolism process [13]. Orlistat reduces the activity of intestinal lipase, reduces the accumulation of fat in the liver, reduces the coding of genes that stimulate lipogenesis, and increases the expression of genes that catabolize lipids [14]. The drug also has a major role in improving the NRF2 signaling pathway, which is the pathway that reduces the risk of atherosclerosis by increasing and activating HDL, which transports cholesterol accumulated in the blood vessels to the liver. This also explains the decrease in cholesterol levels in the groups treated with orlistat [15]. On the other hand, the study showed that the use of liraglutide at both therapeutic and high doses led to a reduced the level of lipid profiles compared to the obese pregnant group. Liraglutide is similar to GLP-1 receptors, whose most important function in the intestine is to reduce the secretion of lipoproteins that have a role in transporting cholesterol and fatty acids. To the blood circulation, and because cholesterol is not hydrophilic, it cannot move into the blood circulation except with the help of lipoproteins, the most prominent examples of which are chylomicrons [16]. When comparing the level of fats in the group of obese pregnant rats and the group of obese pregnant rats with which the herbal supplement Slim Up was used, we notice that there are significant differences. The role of the herbal supplements in lowering the level of triglycerides may be due to the fact that they contain phenolic substances that increase the activity of the adipocyte lipoprotein enzyme. lipase, which converts them into fatty acids and cholesterol, so the concentration of triglycerides decreases. Herbal supplements also work to increase the activity of the enzyme Acyl-coenzyme A: cholesterol acyltransferases (ACAT), which has an active role in transesterifying excess cholesterol, and this is consistent with the current study [17].

Histological changes in maternal obesity

Non-pregnant control group

The results of microscopic examination of the liver of rats in this group showed the normal shape of the liver tissue represented by the central vein around which the hepatic cells are arranged in the form of radial separated from each other by sinusoids containing Kupffer cells, as in figure (1).

Pregnant control group

The microscopic examination of the liver of the pregnant rats showed the normal appearance of the liver tissue consisting of a central vein around which the hepatocytes were arranged in the form

of radial separated by sinusoids. The presence of lymphocytes and a few small fatty vesicles was also observed, as in figure (2).

Obese pregnant group

The appearance of Müller bodies and large and small fatty vesicles was observed, all of which are evidence of the success of induced obesity in rats, in addition to the appearance of fatty degeneration and a large spread of fat droplets that are inside large or small vesicles in the liver cells, as in figure (3).

Obese pregnant group treated with a therapeutic dose of the drug Orlistat

The examination showed a relative improvement in liver tissue when compared to the obese group, but fatty degeneration, cholestasis, lymphocyte infiltration near the central vein continued to appear, in addition to degeneration of the hepatic cell nuclei, as in figure (4).

Obese pregnant group treated with therapeutic doses of liraglutide

Figure (5) showed the continued appearance of fat droplets, which reflects their continued formation inside the liver cells, in which stages of cellular degeneration appear, represented by thickened and degenerated nuclei, in addition to balloon cells, but in lower proportions when compared with the obese group.

Obese pregnant group treated with the herbal supplement (Slim Up)

It was also observed in this group that the histological effects of fat accumulation persisted, as in Figure (6), as deposits of secondary pigments (iron) appeared, and yellow pigments were also deposited as an indication of the destruction of cells and nuclei, and enlargement of Kupffer cells.

Obese pregnant group treated with herbal supplements and therapeutic doses of orlistat

Microscopic examination showed that there was a clear improvement in the tissue in terms of a decrease in the number of fatty vesicles, as their numbers appeared lower, as in figure (7), but fibrin deposition appeared, and lymphocyte enlargement with necrosis.

Obese pregnant group treated with herbal supplements and therapeutic doses of liraglutide

Microscopic examination of the tissues of this group showed that they were almost normal, with a small spread of fatty vesicles, thickening of the nuclei, and cell enlargement, but the arrangement of the sinusoids around the central vein was clear, as in figure (8).

Obese pregnant group treated with over doses of orlistat

Through examination of the liver tissue in this group, it was observed that there was a significant effect, as figure (9) showed the reappearance of Müller bodies in large numbers, thickening of the plasma membrane of most hepatic cells, bleeding, thickening of the wall of the central vein, necrosis and thickening of the nuclei.

Obese pregnant group treated with over doses of liraglutide

Figure (10) shows thickening of the portal vein wall, collapse of the bile duct, and destruction of the walls of the hepatic artery. The endothelial cells surrounding the walls of the central vein also swell.

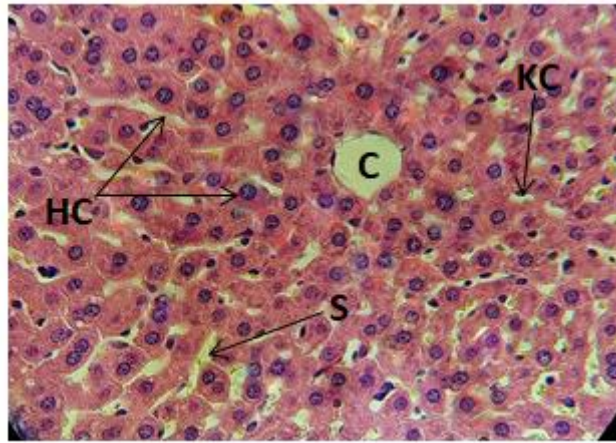


Figure (1): A histological section of a liver from a non-pregnant control group showing the normal shape of the central vein (CV), hepatocytes (HC), Kupffer cells (KC), sinusoids (S), H&E, 400X.

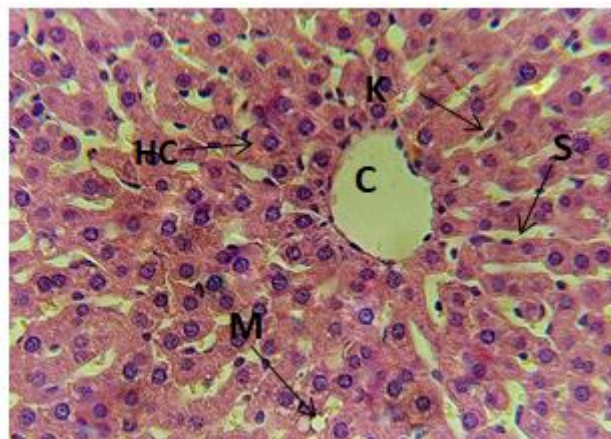


Figure (2): liver of pregnant control group showing the normal shape of the central vein (CV), hepatocytes (HC), Kupffer cells (KC), sinusoids (S), small fatty vesicles (MIV), H&E. ,400X

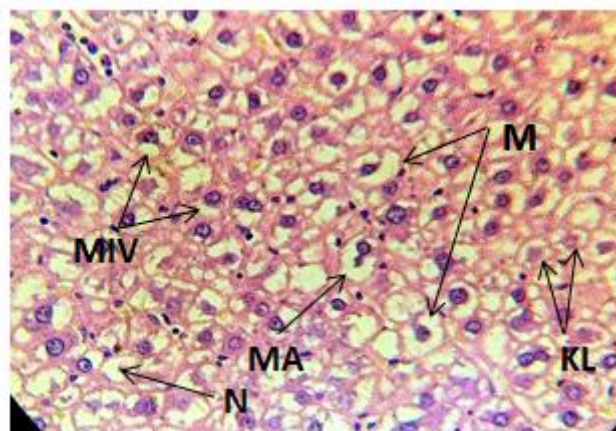


Figure (3): Liver of an obese pregnant group showing the appearance of Müller bodies (MB), large fatty vesicles (MAV) and small (MIV), and karyolysis (KL) H&E. ,400X

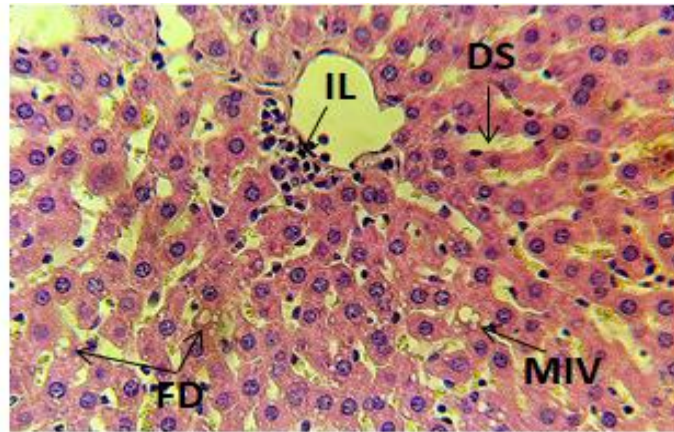


Figure (4): Liver of an obese pregnant group showing the appearance of Müller bodies (MB), large fatty vesicles (MAV) and small (MIV), and karyolysis (KL) H&E. ,400X

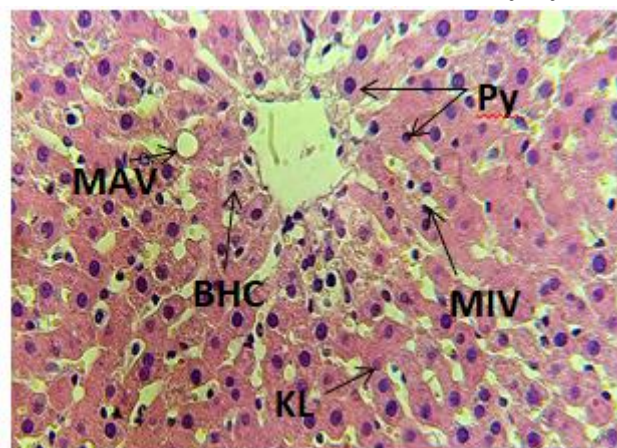


Figure (5): liver of obese pregnant group treated with a therapeutic dose of liraglutide shows small and large fatty vesicles (MAV & MIV), balloon hepatocytes (BHC), thickening of the nuclei (Py), karyolysis of a large portion of the nuclei (KL) H&E. ,400X.

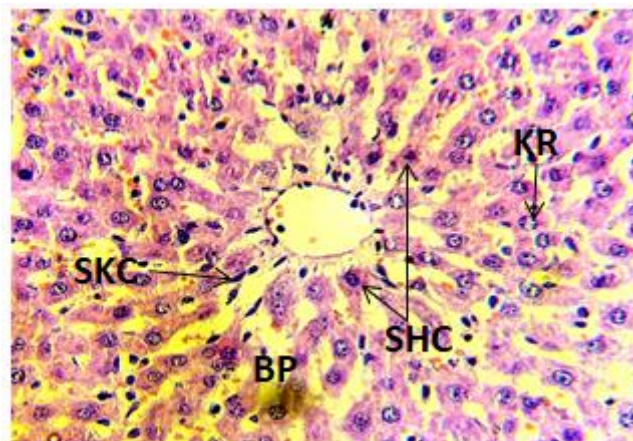


Figure (6): liver of obese pregnant group treated with the herbal supplement showed deposits of secondary pigments (SHC), deposition of bile pigments (BP), rupture of nuclei (KR), and enlargement of Kupffer cells (SKC), H&E. ,400X.

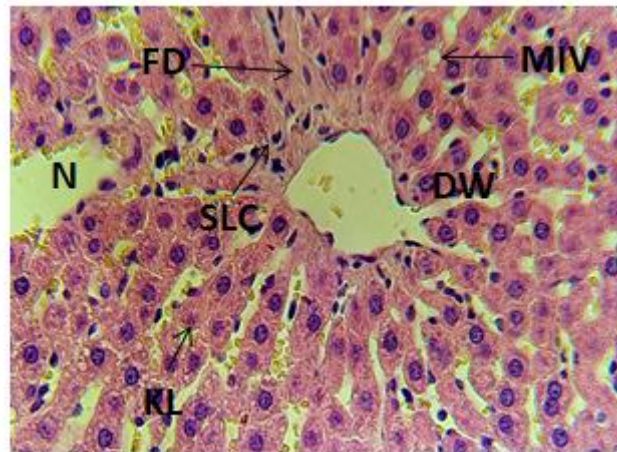


Figure (7): liver of obese pregnant group treated with the herbal supplement and a therapeutic dose of orlistat showing necrosis (N), destruction of the central vein wall (DW), small fatty vesicle (MIV), fibrin deposition (FD), nucleolysis (KL), lymphocytosis (SLC). H&E. ,400X.

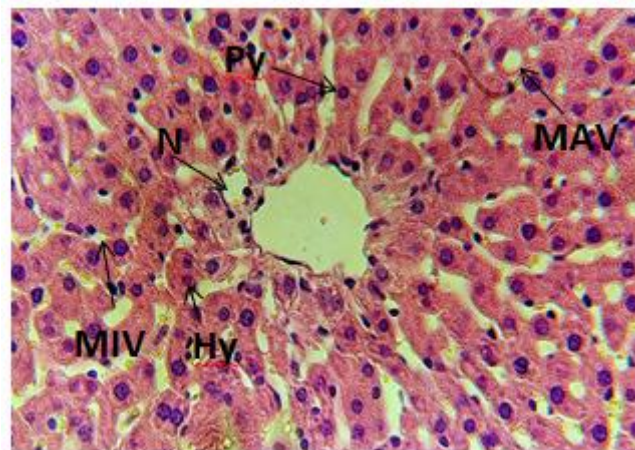


Figure (8): liver of obese pregnant group treated with the herbal supplement and a therapeutic dose of liraglutide showing necrosis (N), destruction of the central vein wall (DW), small fatty vesicle (MIV), fibrin deposition (FD), nucleolysis (KL), lymphocytosis (SLC). H&E. ,400X.

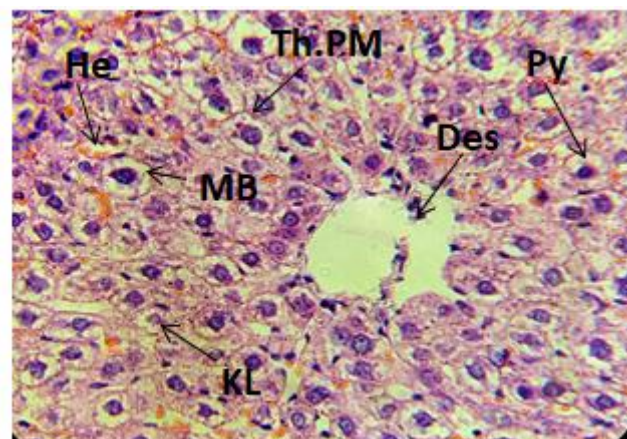


Figure (9): liver of obese pregnant group treated with over dose of orlistat showing desquamation of the central vein wall (Des), thickening of the plasma membranes of hepatocytes (Th.PM), appearance of Müller bodies (MB), hemorrhage (He), karyolysis of nuclei (KL) and thickening (Py) H&E. ,400X.

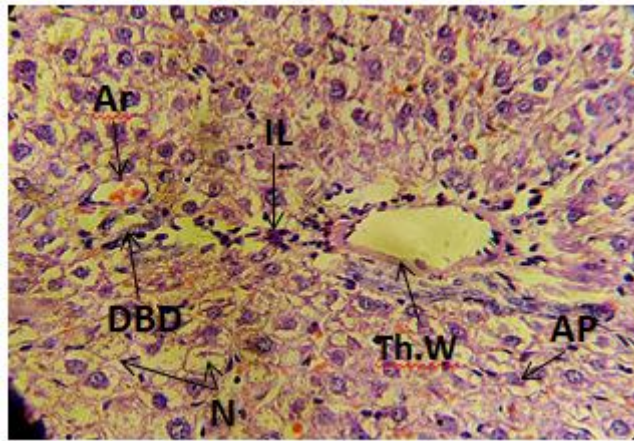


Figure (10): liver of obese pregnant group treated with over dose of liraglutide showing portal vein wall thickens (Th.W), collapse of the bile duct (DBD), destruction of hepatic artery wall (Ar), necrosis (N), and lymphocyte infiltration (IL), apoptosis (AP) H&E. ,400X.

The appearance of fatty vesicles in the liver tissues of pregnant women is explained by the increased need of the fetus for fats as part of the normal growth and development processes, that is, it is considered a normal physiological condition during pregnancy [11]. Therefore, we notice its accumulation in the liver tissues of pregnant women when compared with the liver tissues of non-pregnant women. Microscopic examination of the liver tissue of obese rats treated with a therapeutic dose of orlistat also showed a slight improvement in the levels of proliferation of large and small fatty vesicles and fatty degeneration. The improvement in histopathological lesions may be explained by the fact that the orlistat drug, when it reduces the high levels of fat resulting from a high-fat diet, will restore part of the function. The liver has mutated and changed due to the accumulation of fats in it, on the other hand, microscopic examinations of the liver tissue of obese pregnant rats treated with liraglutide showed histological changes represented by the continued appearance of fatty vesicles and balloon cells, but in relatively lower proportions. Liraglutide at therapeutic doses leads to a reduction in the expression of the gene procollagen type III amino-N-terminal peptide (PIIINP), which is responsible. About liver cell fibrosis, and the drug liraglutide has been proven to increase autophagy processes, including autophagy of fats and repair cells damaged by their accumulation, but at prescribed and fixed doses [18]. When using Orlistat with herbs, a significant improvement in the drug's performance was observed. In an Egyptian study by researchers Sabik et al., [19], who used the drug with green tea, there was a significant improvement in the effect of the drug on tissues because herbs contain several substances that work with different mechanisms and methods, in addition to The drug worked, and this was observed in the current study as well. Histological changes in the liver when using a high dose of drugs may be due to what is known as the negative effects of the drug on the liver (Drug-Induced Liver Injury (DILI), which means that the tissues and cells of the liver are affected by the method of using the drug (through the skin, mouth, intravenous), dose, The period of drug use, when drugs are metabolized in the liver, will change in chemical composition, causing the destruction of some cells, which stimulates oxidative stress that stimulates necrosis or breakdown of the mitochondrial wall [20].

Conclusion

It is concluded from the current study that orlistat and liraglutide in therapeutic doses have an effective role in improving lipid profile levels compared to obese rats, especially when used with the

herb, but double doses of orlistat and liraglutide cause histological effects on the liver of rats.

References

- [1] Umekar, S., & Joshi, A. (2024). Obesity and Preventive Intervention Among Children: A Narrative Review. *Cureus*, 16(2).
- [2] Horwitz, A., & Birk, R. (2023). Adipose Tissue Hyperplasia and Hypertrophy in Common and Syndromic Obesity—The Case of BBS Obesity. *Nutrients*, 15(15), 3445.
- [3] Al Tawil, N. G., Abdulla, M. M., & Abdul Ameer, A. J. (2007). Prevalence of and factors associated with overweight and obesity among a group of Iraqi women. *EMHJ-Eastern Mediterranean Health Journal*, 13 (2), 420-429, 2007.
- [4] Jasim, H. M., Hussein, H. M. A., & Al-Kaseer, E. A. (2018). Obesity among females in Al-Sader city Baghdad, Iraq, 2017. *Journal of the Faculty of Medicine Baghdad*, 60(2), 105-107.
- [5] Hainer, V., & Aldhoon-Hainerová, I. (2014). Tolerability and safety of the new anti-obesity medications. *Drug safety*, 37, 693-702.
- [6] Rössner, S., Sjöström, L., Noack, R., Meinders, A. E., Nosedá, G., & European Orlistat Obesity Study. (2000). Weight loss, weight maintenance, and improved cardiovascular risk factors after 2 years treatment with orlistat for obesity. *Obesity research*, 8(1), 49-61.
- [7] Kumar, M., Kaushik, D., Kaur, J., Proestos, C., Oz, F., Oz, E., ... & Ritika, R. (2022). A critical review on obesity: Herbal approach, bioactive compounds, and their mechanism. *Applied Sciences*, 12(16), 8342.
- [8] Psilopanagioti, A., Nikou, S., Logotheti, S., Arbi, M., Chartoumpakis, D. V., & Papadaki, H. (2022). Glucagon-like peptide-1 receptor in the human hypothalamus is associated with body mass index and colocalizes with the anorexigenic neuropeptide nucleobindin-2/nesfatin-1. *International Journal of Molecular Sciences*, 23(23), 14899.
- [9] Abdelfattah, D. S. E., Fouad, M. A., Elmeshad, A. N., El-Nabarawi, M. A., & Elhabal, S. F. (2024). Anti-Obesity Effect of Combining White Kidney Bean Extract, Propolis Ethanolic Extract and CrPi3 on Sprague-Dawley Rats Fed a High-Fat Diet. *Nutrients*, 16(2), 310.
- [10] Abdul, M.R., Rahim, S.M., Saleh, A.H. Cardioprotective Activity of Costus Root Ethanol Extract in Experimentally-Induced Hypothyroidism in Female Albino Rats. *HAYATI Journal of Biosciences*, 2023; 30(6): 1054–1060.
- [11] Palinski, W. U. L. F., & Napoli, C. (2002). The fetal origins of atherosclerosis: maternal hypercholesterolemia, and cholesterol-lowering or antioxidant treatment during pregnancy influence in utero programming and postnatal susceptibility to atherogenesis. *The FASEB Journal*, 16(11), 1348-1360.
- [12] Hussein, A. A., & Mustafa, N. G. (2024). Impact of a high-fat diet on dyslipidemia and gene expression of low-density lipoprotein receptors in male rats. *Iraqi Journal of Veterinary Sciences*, 38(1), 133-138.
- [13] Semenkovich, C. F. (2006). Insulin resistance and atherosclerosis. *The Journal of clinical investigation*, 116(7), 1813-1822.
- [14] Zhang, Y. X., Jiang, Z. Y., Han, S. L., Li, L. Y., Qiao, F., Zhang, M. L., & Du, Z. Y. (2020). Inhibition of intestinal lipases alleviates the adverse effects caused by high-fat diet in Nile tilapia. *Fish physiology and biochemistry*, 46, 111-123.
- [15] Zakaria, Z., Othman, Z. A., Bagi Suleiman, J., Jalil, N. A. C., Ghazali, W. S. W., & Mohamed, M. (2021). Protective and therapeutic effects of orlistat on metabolic syndrome and oxidative

- stress in high-fat diet-induced metabolic dysfunction-associated fatty liver disease (MAFLD) in rats: Role on Nrf2 activation. *Veterinary sciences*, 8(11), 274.
- [16] Chen, P., Shi, X., Xu, X., Lin, Y., Shao, Z., Wu, R., & Huang, L. (2018). Liraglutide ameliorates early renal injury by the activation of renal FoxO1 in a type 2 diabetic kidney disease rat model. *Diabetes research and clinical practice*, 137, 173-182.
- [17] Woo, M. N., Bok, S. H., Lee, M. K., Kim, H. J., Jeon, S. M., Do, G. M., ... & Choi, M. S. (2008). Anti-obesity and hypolipidemic effects of a proprietary herb and fiber combination (S&S PWH) in rats fed high-fat diets. *Journal of medicinal food*, 11(1), 169-178.
- [18] Salah Nour, M., Sakara, Z. A. E. H., Hasanin, N. A., & Hamed, S. M. (2023). Histological and immunohistochemical study of the effect of liraglutide in experimental model of non-alcoholic fatty liver disease. *Egyptian Journal of Basic and Applied Sciences*, 10(1), 342-357.
- [19] Sabik, L., Metwally, D. E., Mohamed, E., & Elfakharany, Y. (2022). Toxic Effects of Orlistat and Green Tea Extract on Testes of Adult Albino Rats:(Comparative Study). *Zagazig Journal of Forensic Medicine*, 20(1), 99-120.
- [20] Allison, R., Guraka, A., Shawa, I. T., Tripathi, G., Moritz, W., & Kermanizadeh, A. (2023). Drug induced liver injury—a 2023 update. *Journal of Toxicology and Environmental Health, Part B*, 26(8), 442-467.